



Published in final edited form as:

J Inorg Biochem. 2009 November ; 103(11): 1555. doi:10.1016/j.jinorgbio.2009.05.019.

Aluminum hydroxide injections lead to motor deficits and motor neuron degeneration

Christopher A. Shaw^{a,b,c,*} and Michael S. Petrik^c

^a Departments of Ophthalmology and Visual Sciences, University of British Columbia, Vancouver, British Columbia, Canada

^b Experimental Medicine, University of British Columbia, Vancouver, British Columbia, Canada

^c Graduate Program in Neuroscience, University of British Columbia, Vancouver, British Columbia, Canada

Abstract

Gulf War Syndrome is a multi-system disorder afflicting many veterans of Western armies in the 1990–1991 Gulf War. A number of those afflicted may show neurological deficits including various cognitive dysfunctions and motor neuron disease, the latter expression virtually indistinguishable from classical amyotrophic lateral sclerosis (ALS) except for the age of onset. This ALS “cluster” represents the second such ALS cluster described in the literature to date. Possible causes of GWS include several of the adjuvants in the anthrax vaccine and others. The most likely culprit appears to be aluminum hydroxide. In an initial series of experiments, we examined the potential toxicity of aluminum hydroxide in male, outbred CD-1 mice injected subcutaneously in two equivalent-to-human doses. After sacrifice, spinal cord and motor cortex samples were examined by immunohistochemistry. Aluminum-treated mice showed significantly increased apoptosis of motor neurons and increases in reactive astrocytes and microglial proliferation within the spinal cord and cortex. Morin stain detected the presence of aluminum in the cytoplasm of motor neurons with some neurons also testing positive for the presence of hyper-phosphorylated tau protein, a pathological hallmark of various neurological diseases, including Alzheimer's disease and frontotemporal dementia. A second series of experiments was conducted on mice injected with six doses of aluminum hydroxide. Behavioural analyses in these mice revealed significant impairments in a number of motor functions as well as diminished spatial memory capacity. The demonstrated neurotoxicity of aluminum hydroxide and its relative ubiquity as an adjuvant suggest that greater scrutiny by the scientific community is warranted.

Keywords

Aluminum hydroxide; Adjuvant; Neurotoxicity; Gulf War Syndrome; Amyotrophic lateral sclerosis

* Corresponding author. Address: VGH Research Pavilion, 828 W10th Ave., Rm. 386, Vancouver, BC, Canada, V5Z 1L8. Tel.: +604 875 4111x68375; fax: +604 875 4376. cashawlab@gmail.com (C.A. Shaw).

Animal ethics approval: Protocols governing the use of animals were approved by review committees of the University of British Columbia and were in compliance with guidelines published by the Canadian Council on Animal Care and are in accordance with the international guidelines including the NIH Guide for the Care and Use of Laboratory Animals, as well as the EEC Council Directive.

Conflict of interest: None of the authors have received any grants or funding from Bioport, Chiron, Corixa, nor any other pharmaceutical companies named in this article.

1. Introduction

Various studies have established a correlation between Gulf War service (1990–1991) and a multi-system disorder commonly termed Gulf War Syndrome. Included in GWS are various neurological disorders, including an apparent cluster of cases of amyotrophic lateral sclerosis [1–4]. Haley [3] described classical ALS symptoms such as muscle weakness and wasting, impaired speech and swallowing, difficulty in breathing, and fasciculation in Gulf War veterans years after they first developed other symptoms of GWS. Seventeen of the 20 servicemen diagnosed with Gulf War illness and definite ALS were less than 45 years of age with the youngest of these 20 years old. All 20 of these patients presented with signs of upper (motor cortex or bulbar region) and lower (spinal cord) motor neuron degeneration. None of these patients had a family history of ALS or of other neurodegenerative disorders. Horner et al. [2] conducted a nationwide case study performed to identify incidence levels of ALS for the decade after August 1990 amongst active duty members of the military. One hundred and seven confirmed cases of ALS were identified from approximately 2.5 million eligible military personnel. When standardized to the average 1990 US general population, the average annual incidence of ALS among non-deployed military population was 1.4 per 100 000 persons per year compared to the generally accepted overall population incidence of 1.5 cases of ALS per 100 000. The incidence rate of ALS among the deployed military population was 3.6 per 100 000 persons/year. Weisskopf et al. [4] noted a general increase in ALS in US military populations going back a number of decades regardless of the conflict.

ALS–GWS is one of only two ALS disease clusters currently accepted as satisfying the definition of a cluster. The other is the Guamanian variant of ALS first described after World War 2 termed amyotrophic lateral sclerosis parkinsonism dementia complex (ALS–PDC). This spectrum of disorders, once present with an incidence levels hundreds of times higher than in the continental United States [5] (see Kurland, 1988, for review), expressed in one of two ways. The first was as a nearly classical form of ALS; the second was a form of parkinsonism associated with an Alzheimer's disease-like dementia (PDC). About 10% of the victims developed both disorders, with the ALS phenotype typically appearing first. Studies into potential etiologies focused on environmental factors with most attention eventually directed at the consumption of toxin-containing seeds of the local variety of cycad palm [6] and the presence of high aluminum in the soil on southern Guam [7].

In regard to the GWS-ALS AVA vaccine, attention has recently been directed at the anthrax vaccine adsorbed (AVA) and various vaccine ingredients, in particular the known and suspected adjuvants, aluminum hydroxide and squalene [8]. An adjuvant is a substance added during vaccine production designed to non-specifically increase the immune response to an antigen [9]. Aluminum compounds were first identified as adjuvants over 90 years ago. Currently aluminum, in various forms (aluminum hydroxide, aluminum phosphate and aluminum sulfate), is the most commonly licensed adjuvant whose use is generally regarded by both the pharmaceutical industry and the various governmental regulatory agencies as safe [10]. Various studies have found no adverse or long-term health effects due to aluminum adjuvants [11–13] and the Food and Drug Administration (FDA) has continued its longstanding approval for the use of aluminum in this fashion.

In spite of the long history of widespread use, the physicochemical interactions between aluminum compounds and antigens are relatively poorly understood and their underlying mechanisms remain relatively unstudied [14]. It also seems that there have been no rigorous animal studies of potential aluminum adjuvant toxicity. The absence of such studies is peculiar given the well known observation that aluminum in general can be neurotoxic under a number of conditions [15,16] and adjuvants in particular have previously been implicated in neurological disease [17–19]. Table 1 shows the results from previous studies that treated

animals with aluminum hydroxide, listing the resulting impacts on the nervous system. In context to the use of aluminum in vaccines, LD₅₀ values for aluminum hydroxide have not been published to date to the best of our knowledge (J.T. Baker Material Safety Data Sheets).

The potential for aluminum injections to induce macrophagic myofasciitis has also been noted in the literature [20–22].

A previous publication looked at the potential neurotoxicity of several known or suspected vaccine adjuvants [8]. In the current study, we will focus exclusively on the impact of aluminum hydroxide injections on motor and cognitive behaviours and on the expression of different forms of neuropathology in an *in vivo* mouse model.

2. Experimental procedures

2.1. Experimental animals

In our initial study [8], young adult (3 month old) CD-1 male mice were used (approx. 35 g at experiment onset). Younger animals were deliberately chosen to mimic the typical age of service during the Gulf War [3]. Four subcutaneous injection groups (two injections spaced 2 weeks apart) were used: control saline/phosphate buffered solution (PBS) ($n = 10$); aluminum hydroxide ($n = 11$); squalene ($n = 10$); and aluminum hydroxide and squalene ($n = 10$). The current study will report only on the aluminum treated and control groups from this experimental series. A second series of experiments was conducted on 9 month old CD-1 males that received six aluminum hydroxide injections over a 2 weeks period. These mice, along with controls and other treatment groups (to be reported elsewhere), were subjected to a more rigorous behavioural testing regime to be described below. Histological analyses of the spinal cords and brains of these mice are in progress.

All animals in both experiments were singly caged at the Jack Bell Research Centre animal care facility in Vancouver, B.C., Canada. An ambient temperature of 22 °C and a 12/12 h light cycle were maintained throughout the experiment. All mice were fed Purina® mouse chow and given access to both food and water *ad libitum*.

Mice from both studies were sacrificed with an overdose of halothane and transcardially perfused with 4% paraformaldehyde (PFA). CNS tissues were collected for histological examination. Fixed brains and spinal cords from all mice were transferred to a 30% sucrose/PBS solution overnight and then frozen and stored at –80 °C until sectioning. All brain/cord tissue blocks were mounted in Tissue-Tek optimum cutting temperature (O.C.T) compound (Sakura, Zoeterwoude, Netherlands), and then sectioned by cryostat into 30 µm coronal slices. Spinal cords were sectioned at 25 µm in the transverse plane. The sections were cryoprotected in 30% ethylene glycol–20% glycerol–dibasic and monobasic sodium phosphate solution and kept frozen at –20 °C until use.

2.2. Adjuvants

Alhydrogel®, an aluminum hydroxide (Al(OH)₃) gel suspension, was used as a source of aluminum hydroxide. Alhydrogel is manufactured by Superfos Biosector a/s (Denmark) and was purchased from SIGMA Canada.

2.2.1. Doses—To calculate approximate human dosages of aluminum hydroxide for our experiments, we used the following information: The AVA vaccine for human use is made by Bioport Corporation, of Lansing, Michigan. According to product data sheets from the Michigan Biologic Products Institute (MBPI, Lansing, Michigan, USA; Bioport's predecessor), a single dose of AVA vaccine contains 2.4 mg of aluminum hydroxide (equivalent to 0.83 mg aluminum). Based on an assumed average human body weight of 70–80 kg, the amount per

kg body weight would be approximately 30–34 $\mu\text{g}/\text{kg}$. Soldiers or civilians receiving the vaccine would have received between 30–34 $\mu\text{g}/\text{kg}$ (1 injection) and up to approx. 200 $\mu\text{g}/\text{kg}$ if six injections were received.

The adjuvant injections in the treated mice were calibrated based on average animal weight for both experiments. At 3-month-old male CD-1 mice weigh approx. 35 g; at 9 months, the weight is approx. 50 g. In Experiment 1, we performed two injections of a suspension of aluminum hydroxide of (50 $\mu\text{g}/\text{kg}$) in a total volume of 200 μL sterile PBS (0.9%) spaced 2 weeks apart. The mice in this experiment would therefore have received 100 $\mu\text{g}/\text{kg}$ versus a probable 68 $\mu\text{g}/\text{kg}$ in humans. In Experiment 2, mice received six injections for a total of 300 $\mu\text{g}/\text{kg}$ aluminum hydroxide over 2 weeks. Controls in both studies were injected with 200 μL PBS.

The injection site for human administration is typically subcutaneous over the deltoid muscle. For injections in mice we used a subcutaneous injection into the loose skin behind the neck (the “scruff”) to minimize discomfort and for ease of injection.

2.3. Behavioural tests

In the first study, mice were subjected at regular intervals to specific behavioral tests of motor and cognitive function, including wire mesh hang (2 \times /week), open field (1 \times /week), and water maze (1 \times /week) over a 6 months post injection period (see [22]). The order in which the animals were tested was randomized for each trial. In the second study, we conducted a more detailed behavioural examination based on the automated EthoVision system (Noldus Information Technology, Seattle, WA) employing a video camera and tracking software (Noldus EthoVision[®] 3.1). Individual movements of the mice were tracked for 5 min in an open field at weekly intervals. The software allowed for quantitative measurements of a variety of motor functions, including distance moved, percentage of time moving, velocity, and a variety of others. These latter experiments continued for 28 weeks following the last injections.

2.4. Histological measurements (Experiment 1)

2.4.1. NeuN and active caspase-3—As cited in Petrik et al. [8], five mice were used from each treatment group. In each, multiple brain ($n = 3$) and spinal cord ($n = 8$) sections at different levels were examined. Fluorescent intensity levels of NeuN and activated caspase-3 were used to identify neurons and cells dying by apoptosis, respectively. Regions of interest were defined using landmarks from mouse brain and spinal cord stereotaxic atlases [23,24]. All sections were counted in an unbiased manner under a 40 \times objective.

2.4.2. Choline acetyltransferase (ChAT) and Glial fibrillary acidic protein (GFAP)—As cited in Petrik et al. [8], the ChAT antibody was used to identify cholinergic motor neurons in the brain and spinal cord [25,26]. GFAP was used to label reactive astrocytes [27, 28].

2.4.3. Iba-1—A rabbit polyclonal antibody against the ionized calcium binding adapter molecule (Iba-1) (Wako, Richmond, VA, USA) was used to stain for activated microglia [29]. For Iba-1 fluorescent immunolabeling, staining followed the same protocol used for GFAP labeling except for the following modification: Sections were incubated with primary rabbit-anti-Iba-1 (in PBST with 1% NGS + 1% BSA; 1:1000 dilution) overnight at 4 °C. Sections were then incubated in anti-rabbit AlexaFluor 546[™] secondary antibody for 2 h at room temperature (Molecular Probes; Eugene, OR, 1:200).

2.4.4. Morin (3,5,7,2',4'-pentahydroxyflavone, BDH)—Morin (M4008-2G, Sigma) is a fluorochrome which forms a fluorescent complex with aluminum fluorescing green (with an

excitation wavelength of 420 nm) [15,30] when it does so. The aluminum-Morin fluorescence assay was used for the visualization and detection of aluminum in lumbar spinal cord and other CNS tissues in the present experiments. The Morin stain was used as a 0.2% solution in 85% ethyl alcohol containing 0.5% acetic acid. All mounted sections were first washed with PBS twice for 5 min. Sections were then pretreated for 10 min in a 1% aqueous solution of hydrochloric acid, rinsed in double distilled water (ddH₂O) twice for 5 min, and immersed in 0.2% Morin stain for 10 min. The sections were then washed in ddH₂O twice for 5 min, dehydrated in 70%, 90%, and 100% ethyl alcohol (EtOH), and cleared with 100% xylene. All sections were then mounted using Vectashield mounting medium (Vector Laboratories), sealed with clear nail polish, and allowed to air dry.

2.4.5. Staining for hyper-phosphorylated tau protein—Hyper-phosphorylated tau (Anti-Human PHF-Tau, Pierce Biotechnology, Inc., Rockford, IL) labeling was determined using the non-fluorescent diaminobenzidine (DAB) method. Slides containing mounted sections of lumbar spinal cord were first rinsed twice PBS (2× 5 min) before performing antigen unmasking. Endogenous peroxidase activity was quenched using 0.3% hydrogen peroxide in methanol for 20 min. The sections were rinsed twice in PBS (2× 5 min) before blocking at room temperature for 1 h in M.O.M. blocking reagent (M.O.M. Kit – peroxidase, cat # PK 2200, Vector Laboratories, Inc., Burlingame CA) followed by a quick rinse in PBS and a 5 min incubation in M.O.M. diluent solution. The primary PHF-Tau antibody was diluted 100× in M.O.M. diluent solution and incubation was conducted at room temperature for 1 h. After the primary antibody incubation step, the slides were rinsed twice in PBS, and then incubated in the M.O.M. biotinylated anti-mouse IgG reagent for 10 min. The sections were rinsed in PBS before incubating with the secondary antibody (Vectastain ABC Elite Kit, cat # PK-6101) for 1 h at room temperature followed by incubation in the Vectorstain ABC Elite Reagents for another 30 min. The slides were rinsed again in 1× PBS. Color development was achieved using the Vector ImmPACT™ DAB solution (cat # SK-4105). When the desired color was achieved, the slides were rinsed in ddH₂O for 5 min and counter-stained in 0.1% methyl green for 5 min. After counter-staining, the slides were rinsed briefly in ddH₂O, two changes of 95% ethanol and two changes of 100% ethanol. The slides were allowed to dry before they were mounted in Permount® (Fisher Scientific, Fair Lawn, NJ).

2.5. Microscopy

Brain and spinal cord sections processed with fluorescent antibodies or DAB were viewed with a Zeiss Axiovert 200 M (Carl Zeiss Canada Limited, Toronto, ON, Canada) microscope at 40× and 100× (under oil) magnification. DAPI (blue fluorescence) was viewed with a 359/461 nm absorption/emission filter. Alexa Fluor 546™ (red), and rabbit IgG DuoLuX™ (red) were viewed with 556 557/572 573 nm filter. FITC was viewed with a 490 494/520 525 nm filter. Brain and lumbar spinal cord sections for histology were chosen randomly for each group. When counting using 40× magnification two images were captured per spinal cord section: ventral left, ventral right. 40× images were 350 × 275 μm and 100× images were 50 × 115 μm. Images were captured using AxioVision 4.3 software.

2.6. Criteria for determination and quantification of labeled cells

For quantification, only cells that were in focus and completely within the field of view were counted. To eliminate the likelihood that the same cell would be counted twice, slices for each histological experiment were drawn from only one well of the collection dish to ensure that sections were at least 250 μm apart. Regions of interest for cell counts were defined using landmarks and reference points from mouse spinal cord and brain stereotaxic atlases [39,40]. In the spinal cord, only cells which were anterior to the central canal and deep apex where the grey and white matters meet were considered as part of the ventral horns; conversely, only cells which were posterior to the central canal and the posterior deep apex were considered as

part of the dorsal horns. These criteria applied regardless of the spinal segments examined. In the brain, only cells found within the corresponding brain structures were counted. All sections were counted in an unbiased manner (a code key was assigned to the animals for tracking purposes, but did not reveal the identity of treatment the animal was prescribed).

2.7. Statistics

Values for each mouse on the individual tasks and in the cell counts were used to calculate mean \pm S.E.M. for each group and condition. Behavioral scores and cell counts were normalized to the mean value of controls. The means were compared using one- or two-way ANOVA (Statistica, Statsoft Inc., Tulsa, OK; GraphPad Prism, San Diego, CA).

3. Results

Unlike the Petrik et al. [8] study which showed a loss of ChAT positive motor neurons in the lumbar cord of aluminum hydroxide treated mice, there was no significant difference in ChAT labeling or motor neuron counts in either the cervical or thoracic spinal cord segments (Fig. 1A and B). However, the aluminum injected group showed a highly significant increase in the expression of GFAP positive astrocytes (70%) are the control group (listed as 100% for all graphs; Fig. 1C) in the cervical segment of spinal cord. These GFAP results mirrored the outcomes previously reported in lumbar cord.

Iba-1 labeling demonstrated significantly increased levels of activated microglia in the lumbar spinal cord of animals injected with aluminum (111%) compared to controls (Fig. 1E). Other levels of cord were not tested for microglia in the present study.

Only mice injected with aluminum hydroxide showed significantly increased Morin labeling of cells in lumbar spinal cord compared to the other groups (Fig. 2A–E). Similarly, only aluminum-injected mice showed the presence of abnormal tau protein in motor neurons in lumbar cord (Fig. 3). Other regions of the cord were not tested in the current studies for either Morin or tau protein.

The multiple aluminum hydroxide injections of experiment 2 showed profound effects on motor and other behaviours as shown in Figs. 4 and 5. Multiple aluminum injections produced significant behavioural outcomes including changes in locomotive behaviour, (Fig. 4) and induced memory deficits on water maze tasks (Fig. 5). Other behavioural measures including muscle strength and endurance as measured by the wire hang and motor coordination and balance as measured by rotarod were not significantly affected.

4. Discussion

The current results extend the preliminary results reported by Petrik et al. [8] by showing that microglial activation is part of the underlying pathology in the lumbar cord. These data add to those previously reported, i.e., the loss of motor and other neurons and the activation of reactive astrocytes. Taken together with the current data, the overall activation of a glial inflammatory response in lumbar cord suggests that this process is a key early stage of the pathological events leading to motor neuron death. This interpretation is supported by an absence of motor neuron loss and astrocyte activation in the other levels of the spinal cord observed in the present study. In ALS and in animal models of the disease, glial activation followed by motor neuron death often appears to proceed in sequential manner along the ventral neuraxis with the first signs of pathology appearing first in lumbar cord [31]. Given this, it seems possible that an examination of later time points would show pathological responses in the thoracic and cervical cord as well. Alternatively, the aluminum shown to be present in lumbar cord motor neurons may not

have reached these other spinal cord segments. Studies now in progress will determine if motor neurons in these other segments stain positively for aluminum.

The positive Morin staining in lumbar cord clearly demonstrates that post injection aluminum finds entry into this part of the nervous system. One possibility is that it does so by retrograde transport from muscles to motor neurons in particular segments. This seems unlikely given that our paradigm of injecting *subcutaneous* should not have targeted any particular spinal cord segment. Another possibility is that aluminum can enter the CNS in a systemic manner if it enters the circulatory system. Experiments in progress are designed to distinguish between these possibilities.

The presence of hyper-phosphorylated tau protein, one of the hallmarks of both Alzheimer's disease and ALS-PDC of Guam, in motor neurons in lumbar spinal cord clearly suggests that additional pathological processes associated with aluminum are occurring.

The behavioural outcomes in the second experiment reported here reinforce the pathological outcomes seen in the first studies. While the histological measurements from these studies are still pending, the extent of the behavioural deficits strongly suggests that we will observe widespread neuronal pathologies. The greater extent of the behavioural outcomes in this experiment may be related to the experimental paradigm that tripled the number of aluminum hydroxide injections.

Overall, the results reported here mirror previous work that has clearly demonstrated that aluminum, in both oral and injected forms, can be neurotoxic [15,16,32,33]. Potential toxic mechanisms of action for aluminum may include enhancement of inflammation (i.e., microgliosis) and the interference with cholinergic projections [34], reduced glucose utilization [33], defective phosphorylation-dephosphorylation reactions [35], altered rate of transmembrane diffusion and selective changes in saturable transport systems in the blood brain barrier (BBB [36], and oxidative damage on cellular processes by the inhibition of the glutathione redox cycle [37].

Given the above, it is not surprising that aluminum has been widely proposed as a factor in neurodegenerative diseases and has been found in association with degenerating neurons in specific CNS regions [38–41]. In animal studies, aluminum has been linked to the accumulation of tau protein and amyloid-beta protein and observed to induce neuronal apoptosis *in vivo* as well as *in vitro*³⁰. Aluminum injected animals show severe anterograde degeneration of cholinergic terminals in cortex and hippocampus [42].

Aluminum in its adjuvant form can gain access to the CNS [42–44], however, oral administration of aluminum hydroxide gel does not appear to be neurotoxic in humans [45], although aluminum chloride is, in rats [46]. The route of exposure, and perhaps the form of aluminum, may be important factors that determine the potential for toxicity.

We speculate that the observed neurotoxic effects of aluminum hydroxide in the present study arise by both 'direct' and 'indirect' pathways, some of which are cited above. Direct toxicity refers to the physical presence (or close proximity) of aluminum and its potential for initiating cell death pathways. Accumulation of aluminum into the cytoplasm via cellular uptake mechanisms or diffusion could cause alterations in glutaminase and glutamine synthetase and easily alter the availability of the neurotransmitter glutamate [47]. Aluminum acting to induce abnormal tau protein accumulation could also increase neurofibrillary tangles and impair cellular transport mechanisms [48]. Outside the cell, aluminum could affect neurons by altering synapses. For example, aluminum has been shown to decrease the thickness of post-synaptic density, increase the width of the synaptic cleft, and increase the number of flat synapses [49]. Aluminum could also block voltage-activated calcium channels [50], augment the activity

of acetylcholinesterase [51], or interfere with synaptic transmission by merely accumulating in the synaptic cleft [52]. Aluminum can also induce apoptosis in astrocytes [53]. Since astrocytes are essential for maintaining neuronal health, any loss of astrocyte function could prove toxic to neurons. Indirect toxicity of aluminum could occur in various ways, including by activating various cytokines [54], releasing glutamate in an excitotoxic cascade, or by modifying various enzymatic pathways [55].

In addition to the above actions specifically on neural cells, aluminum might act indirectly by stimulating abnormal, generalized immune responses. This is, in fact, what adjuvants are placed in vaccines to do in the first place. Adjuvant neurotoxicity could thus be the result of an imbalanced immune response. Rook and Zumla [56] hypothesized that multiple vaccinations, stress, and the method of vaccination could lead to a shift in immune response [56,57]. Aluminum hydroxide has previously been shown to stimulate a Th2-cytokine response [9, 58].

While the current results and our previous study have demonstrated significant behavioural and neuropathological outcomes with aluminum hydroxide and some additionally significant outcomes due to a combination of adjuvants, it is important to recognize that these were achieved under *minimal* conditions. Table 1 summarizes aspects of human ALS and GWS symptoms compared with outcomes observed in aluminum-injected mice. The likelihood exists that a synergistic effect between adjuvants and other variables such as stress, multiple vaccinations, and exposure to other toxins likely occurs. A recent study examining some of these factors in combination showed that stress, vaccination, and pyridostigmine bromide (a carbamate anticholinesterase (AChE) inhibitor), may synergistically act on multiples stress-activated kinases in the brain to induce neurological impairments in GWS [59]. In addition, a genetic background in context to aluminum exposure may play a crucial role and may be an important area for future research.

The demonstration of neuropathological outcomes and behavioural deficits in aluminum hydroxide injected mice may provide some insight into the causes of not only GWS–ALS, but may open avenues of investigation into other neurological diseases.

Acknowledgments

This work was supported by grants from the Scottish Rite Charitable Foundation of Canada and the Natural Science and Engineering Research Council of Canada (to CAS). We thank Dr. Meryl Nass (Mount Desert Island Hospital, Maine, USA) and Lt. Col. John A. Richardson (USAFR, ret.) for their invaluable comments and advisory contributions to this project and manuscript.

References

1. Charatan F. *BMJ* 2002;324:65. [PubMed: 11786440]
2. Horner RD, Kamins KG, Feussner JR, Grambow SC, Hoff-Lindquist J, Harati Y, Mitsumoto H, Pascuzzi R, Spencer PS, Tim R, Howard D, Smith TC, Ryan MA, Coffman CJ, Kasarskis EJ. *Neurology* 2003;61:742–749. [PubMed: 14504315]
3. Haley RW. *Neurology* 2003;61:750–756. [PubMed: 14504316]
4. Weisskopf MG, O'Reilly EJ, McCullough ML, Calle EE, Thun MJ, Cudkovicz M, Ascherio A. *Neurology* 2005;64:32–37. [PubMed: 15642900]
5. Kurland LT. *Trends Neurosci* 1988;11:51–54. [PubMed: 2465598]
6. Whiting MG. *Econ Bot* 1963;17:271–302.
7. Garruto RM, Shankar SK, Yanagihara R, Salazar AM, Amyx HL, Gajdusek DC. *Acta Neuropathol Berl* 1989;78:210–219. [PubMed: 2750490]
8. Petrik MS, Wong MC, Tabata RC, Garry RF, Shaw CA. *Neuromol Med* 2007;9:83–100.

9. Brewer JM, Conacher M, Hunter CA, Mohrs M, Brombacher F, Alexander J. *J Immunol* 1999;163:6448–6454. [PubMed: 10586035]
10. Lindblad EB. *Vaccine* 2004;22:3658–3668. [PubMed: 15315845]
11. Baylor NW, Egan W, Richman P. *Vaccine* 2002;20(Suppl 3):S18–S23. [PubMed: 12184360]
12. Kanra G, Viviani S, Yurdakok K, Ozmert E, Anemona A, Yalcin S, Demiralp O, Bilgili N, Kara A, Cengiz AB, Mutlu B, Baldini A, Marchetti E, Podda A. *Pediatr Int* 2003;45:314–318. [PubMed: 12828588]
13. Jefferson T, Rudin M, Di Pietrantonj C. *Lancet Infect Dis* 2004;4:84–90. [PubMed: 14871632]
14. Lindblad EB. *Immunol Cell Biol* 2004;82:497–505. [PubMed: 15479435]
15. Crapper DR, Krishnan SS, Dalton AJ. *Science* 1973;180:511–513. [PubMed: 4735595]
16. Kawahara M, Kato M, Kuroda Y. *Brain Res Bull* 2001;55:211–217. [PubMed: 11470317]
17. Garruto RM, Yanagihara R, Gajdusek DC. *Neurology* 1985;35:193–198. [PubMed: 3969206]
18. Wagner-Recio M, Toews AD, Morell P. *J Neurochem* 1991;57:1891–1901. [PubMed: 1940905]
19. Bilkei-Gorzo A. *Food Chem Toxicol* 1993;31:357–361. [PubMed: 8505021]
20. Verdier F, Burnett R, Michelet-Habchi C, Moretto P, Fievet-Groynne F, Sauzet E. *Vaccine* 2005;23:1359–1367. [PubMed: 15661384]
21. Kalil RK, Monteiro A Jr, Lima MI, Silveira EB, Foltran FS, Martins CE, Rizzo IM. *Ultrastruct Pathol* 2007;31:45–50.
22. Exley C, Swarbrick L, Gherardi RK, Authier FJ. *Med Hypotheses* 2009;72:135–139. [PubMed: 19004564]
23. Sidman, RL.; Angevine, JB., Jr; Pierce, ET. *Atlas of the Mouse Brain and Spinal Cord*. Harvard University Press; Massachusetts: 1971.
24. Paxinos, G.; Franklin, KBJ. *The Mouse Brain in Stereotaxic Coordinates*. second. Academic Press; San Diego: 2001.
25. Wetts R, Vaughn JE. *Exp Neurol* 1996;141:248–255. [PubMed: 8812158]
26. Maatkamp A, Vlug A, Haasdijk E, Troost D, French PJ, Jaarsma D. *Eur J Neurosci* 2004;20:14–28. [PubMed: 15245475]
27. Lee VM, Page CD, Wu HL, Schlaepfer WW. *J Neurochem* 1984;42:25–32. [PubMed: 6358415]
28. Tohyama T, Lee VM, Rorke LB, Trojanowski JQ. *J Comp Neurol* 1991;310:285–299. [PubMed: 1787174]
29. Imai Y, Ibata I, Ito D, Ohsawa K, Kohsaka S. *Biochem Biophys Res Commun* 1996;224:855–862. [PubMed: 8713135]
30. De Boni U, Scott JW, Crapper DR. *Histochemistry* 1974;40:31–37. [PubMed: 4136834]
31. Tabata RC, Wilson JMB, Ly P, Zwieggers P, Kwok D, Van Kampen JM, Cashman N, Shaw CA. *Neuromol Med* 2008;10:24–39.
32. Banks WA, Kastin AJ. *Neurosci Biobehav Rev* 1989;13:47–53. [PubMed: 2671833]
33. Joshi JG. *Biofactors* 1990;2:163–169. [PubMed: 2198876]
34. Platt B, Fiddler G, Riedel G, Henderson Z. *Brain Res Bull* 2001;55:257–267. [PubMed: 11470325]
35. Cordeiro JM, Silva VS, Oliveira CR, Goncalves PP. *J Inorg Biochem* 2003;97:132–142. [PubMed: 14507469]
36. Kaya M, Kalayci R, Arican N, Kucuk M, Elmas I. *Biol Trace Elem Res* 2003;92:221–230. [PubMed: 12794274]
37. Murakami NJ. *J Neurol* 1999;256(Suppl 2):II16–II18. [PubMed: 10525998]
38. Perl DP, Gajdusek DC, Garruto RM, Yanagihara RT, Gibbs CJ. *Science* 1982;217:1053–1055. [PubMed: 7112111]
39. Perl DP, Penderbury WW. *Can J Neurol Sci* 1986;13:441–445. [PubMed: 3791060]
40. Rao JK, Katselos CD, Herman MM, Savory J. *Clin Lab Med* 1998;18:687–698. [PubMed: 9891607]
41. Savory J, Garruto RM. *Nutrition* 1998;14:313–314. [PubMed: 9583377]
42. Wen GY, Wisniewski HM. *Acta Neuropathol (Berl)* 1985;68:175–184. [PubMed: 2417440]
43. Redhead K, Quinlan GJ, Das RG, Gutteridge JM. *Pharmacol Toxicol* 1992;70:278–280. [PubMed: 1608913]

44. Sahin G, Varol I, Temizer A, Benli K, Demirdamar R, Duru S. *Biol Trace Elem Res* 1994;41:129–135. [PubMed: 7946900]
45. Rosati G, De Bastiani P, Gilli P, Paolino E. *J Neurol* 1980;223:251–257. [PubMed: 6157787]
46. Walton JR. *Neurosci Lett* 2007;412:29–33. [PubMed: 17156917]
47. Zielke HR, Jackson MJ, Tildon JT, Max SR. *Mol Chem Neuropathol* 1993;19:219–233. [PubMed: 8104402]
48. Bizzi A, Crane RC, Autilio-Gambetti L, Gambetti P. *J Neurosci* 1984;4:722–731. [PubMed: 6200578]
49. Jing Y, Wang Z, Song Y. *Synapse* 2004;15:292–298. [PubMed: 15103695]
50. Busseberg D, Platt B, Haas HL, Carpenter DO. *Brain Res* 1993;622:163–168. [PubMed: 8242354]
51. Zatta P, Ibn-Lkhatay-Idrissi M, Zambenedetti P, Kilyen M, Kiss T. *Brain Res Bull* 2002;59:41–45. [PubMed: 12372547]
52. Banin E, Meiri H. *Brain Res* 1987;423:359–363. [PubMed: 3676813]
53. Aremu DA, Meshitsuka S. *Brain Res* 2005;1031:284–296. [PubMed: 15649454]
54. Johnson VJ, Sharma RP. *Neurotoxicity* 2003;24:261–268.
55. Nayak P, Chatterjee AK. *Food Chem Toxicol* 2001;39:1285–1289. [PubMed: 11696403]
56. Rook GA, Zumla A. *Lancet* 1997;349:1831–1833. [PubMed: 9269228]
57. Rook GA, Zumla A. *Hosp Med* 1998;59:10–11. [PubMed: 9798557]
58. Valensi JP, Carlson JR, Van Nest GA. *J Immunol* 1994;153:4029–4039. [PubMed: 7930610]
59. Wang D, Perides G, Liu YF. *J Neurochem* 2005;93:1010–1020. [PubMed: 15857404]

Abbreviations

chE	Anticholinesterase
ALS–PDC	Amyotrophic lateral sclerosis- parkinsonism dementia complex
AVA	Anthrax vaccine adsorbed
BSA	Bovine serum albumin
GFAP	Glial fibrillary acidic protein
ChAT	Choline acetyltransferase
GWS	Gulf War Syndrome
NGS	normal goat serum
OCT	Optimum cutting temperature
PBST	Phosphate buffer saline – Tween 20
PFA	Paraformaldehyde

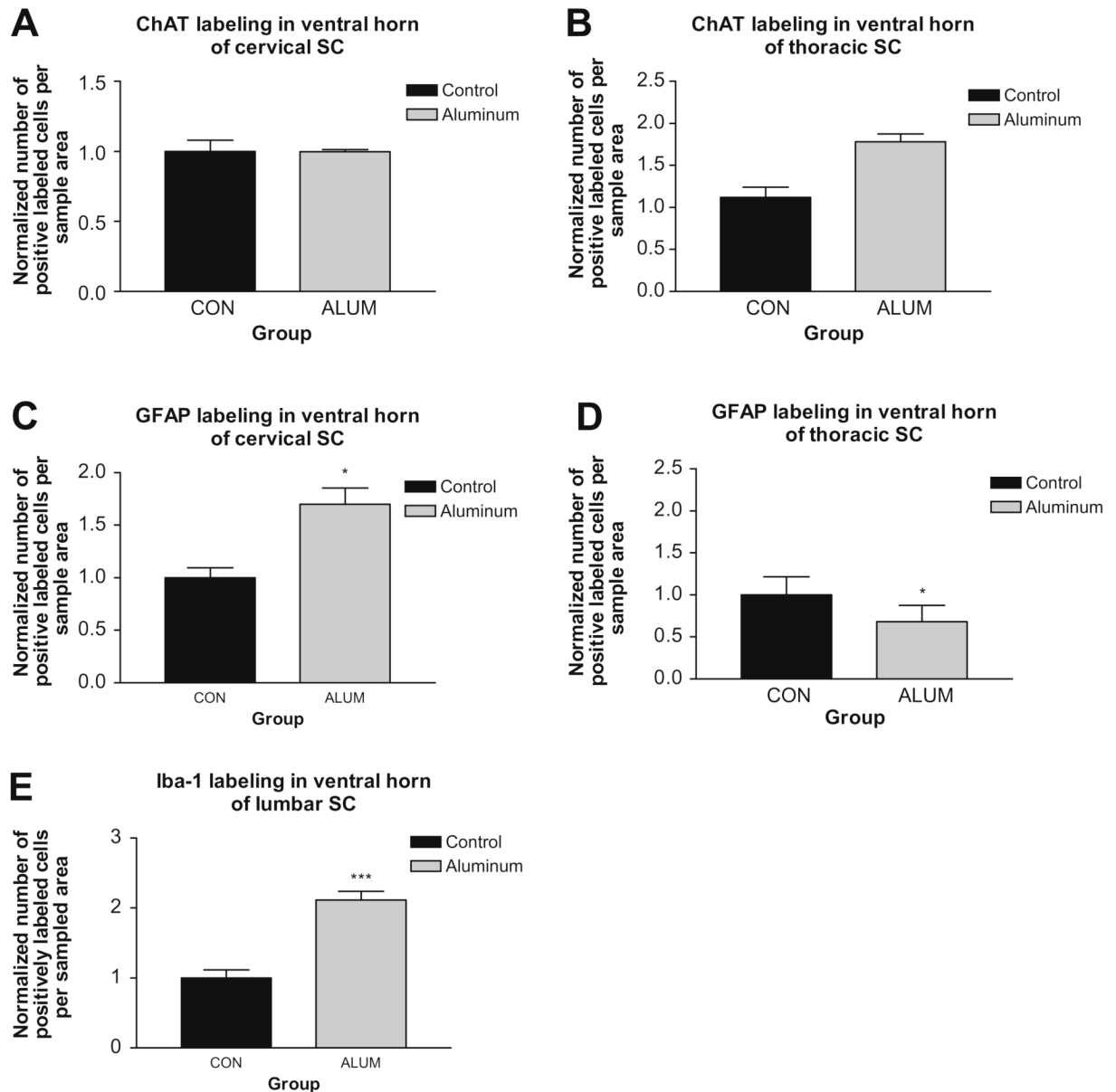


Fig. 1. Impact of aluminum hydroxide on different levels of spinal cord (SC). (A and B) ChAT labeling in cervical and thoracic cords, respectively. (C and D) Normalized cell counts for GFAP labeling of reactive astrocytes in cervical and thoracic spinal cord, respectively. In cervical cord, the aluminum hydroxide treated groups showed higher levels of GFAP labeling with the aluminum alone group achieving statistical significance. (E) Iba-1 fluorescent labeling in the ventral horn of mouse lumbar cord showed that aluminum-injected mice had significantly increased numbers of activated microglia. Data are means \pm S.E.M. *** $p < 0.001$, one-way ANOVA.

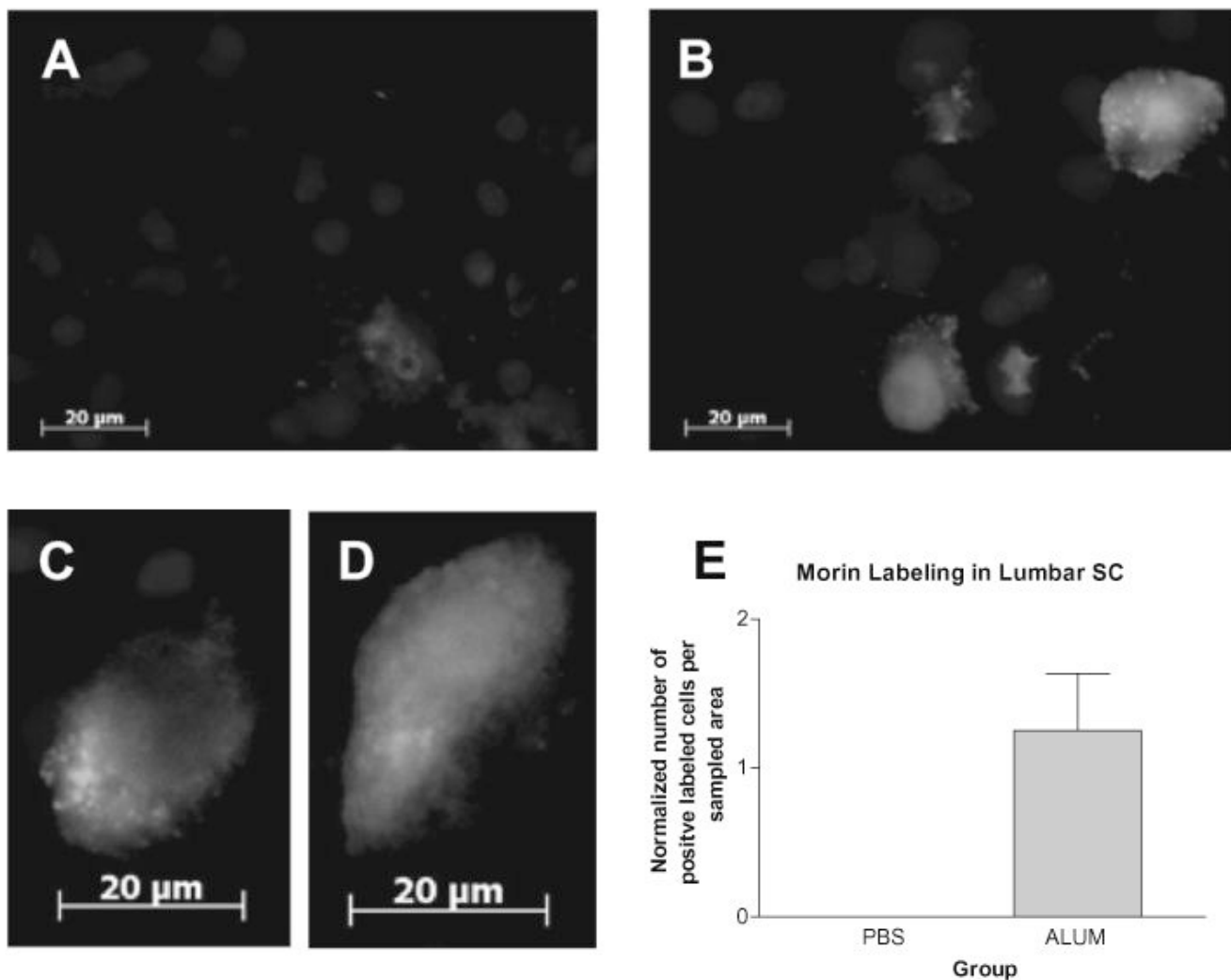


Fig. 2. Morin fluorescent labeling in ventral horn of mouse lumbar spinal cord. Sections from control (A) mice showed no Morin fluorescent labeling. Scale bar = 20 μm. (B) Morin-positive motor neurons in aluminum hydroxide treated mice. (C and D) Higher power of motor neurons in aluminum-injected mice showing show high levels of cytoplasmic Morin labeling. Scale bar = 20 μm. (E) Cell counts for Morin positive cells in the different treatment groups ($n = 4$ mice/group, four sections each). Data are mean \pm S.E.M. One-way ANOVA analysis revealed a significance level of $*p < 0.05$.

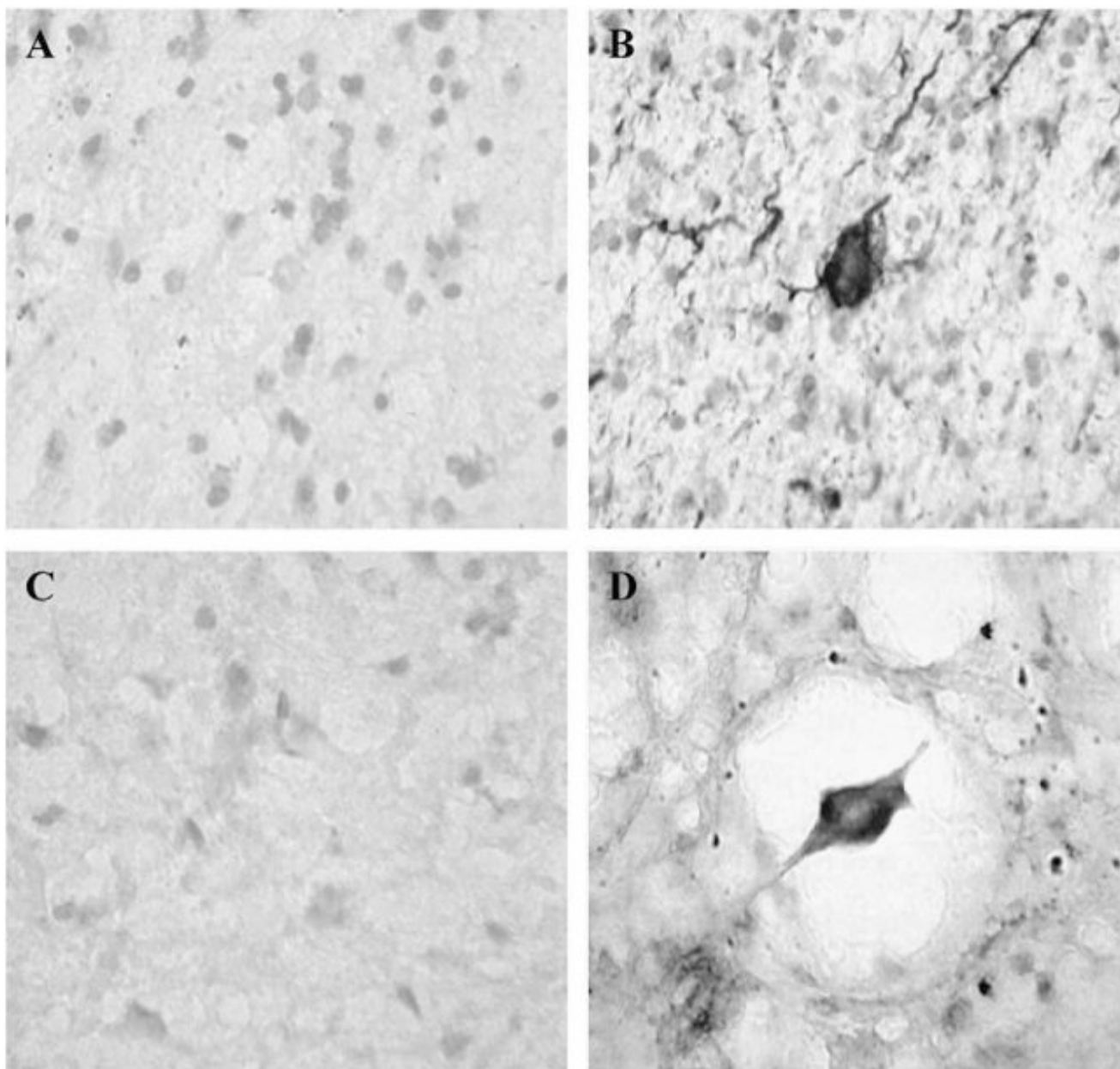


Fig. 3. Hyper-phosphorylated tau immunostaining in the ventral horn of mouse lumbar spinal cord compared to Alzheimer's disease. (A) A section of human entorhinal cortex from a control patient. (B) Human entorhinal cortex section from a patient with Alzheimer's disease (sections kindly provided courtesy of Dr. P. McGeer). (C) Lumbar spinal cord sample from a saline injected mouse. (D) Equivalent section from an aluminum hydroxide injected mouse. All pictures are 100× magnification.

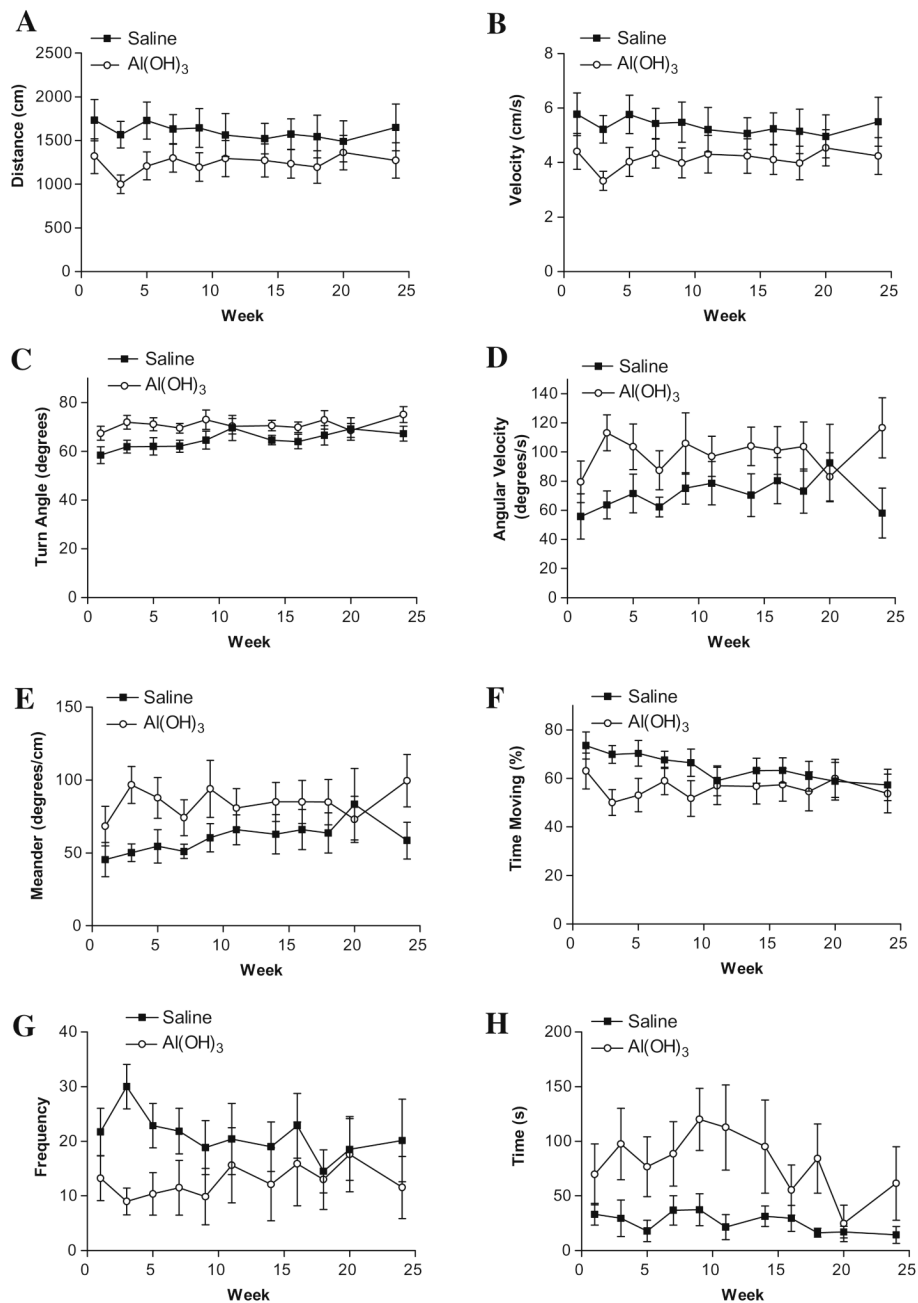


Fig. 4. Open field movement analysis as an assessment of spontaneous activity and anxiety in control mice vs. mice injected six times with aluminum hydroxide. Aluminum hydroxide injected mice showed the following behavioural changes: (A) Shorter distances moved ($***p < 0.0001$). (B) Slower movement ($***p < 0.0001$). (C) Greater mean turn angle ($***p < 0.0001$). (D) More rapid turning ($***p < 0.0001$). (E) Greater meander ($***p < 0.0001$). (F) Smaller percentage of time in overall movement ($**p = 0.0030$). (G) Fewer entries into the centre of the open field ($***p < 0.001$). Late entry into centre ($***p < 0.0001$). (All measures, two-way ANOVA).

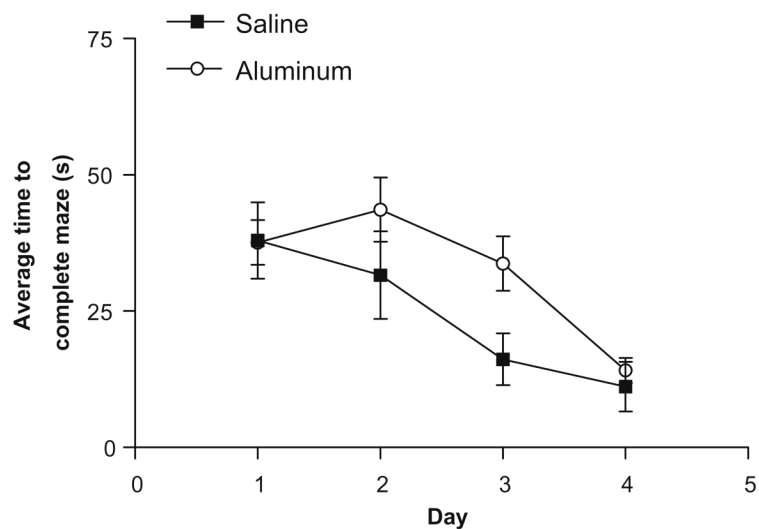


Fig. 5. Water maze test as an evaluation of learning and memory. Mice injected 6× with aluminum hydroxide on average took significantly longer to complete the maze compared to saline injected mice (two-way ANOVA. * $p = 0.0389$).

Table 1

Summary of human ALS and GWI symptoms compared with symptoms observed in aluminum-treated mice and rats. This table also outlines the similarities between human ALS and Gulf War illness.

Animal	Age	Dose	Injection type	Result	Reference
Female NIH mice	4 week	315–335 µg/kg	i.p.	Significantly elevated levels of Al in brain	Redhead et al., 1991
Male and female Long Evan rats	2 month	100 or 300 mg/kg/day	Oral	Significantly reduced learning ability and elevated levels of Al in brain	Bilkei-Gorzo, 1993
Male Swiss albino mice	Not stated	~20 µg/kg/day	Oral	Significantly elevated levels of Al in brain, kidney and liver.	Sahin et al., 1994
Pzh:SFIS mice	Not stated	1.0 mg every 2 weeks or 0.1 mg 5 days/week	i.p.	Significantly elevated levels of Al in liver and tibia (bone), but not in brain.	Fiejka et al., 1996